

9-1986

Azathioprine-Induced Reversible Severe Dyserythropoiesis as a Cause of Anemia

Sundara B. K. Raman

Joseph P. Abraham

Sheikh M. Saeed

Maria Sawdyk

Follow this and additional works at: <https://scholarlycommons.henryford.com/hfhmedjournal>



Part of the [Life Sciences Commons](#), [Medical Specialties Commons](#), and the [Public Health Commons](#)

Recommended Citation

Raman, Sundara B. K.; Abraham, Joseph P.; Saeed, Sheikh M.; and Sawdyk, Maria (1986) "Azathioprine-Induced Reversible Severe Dyserythropoiesis as a Cause of Anemia," *Henry Ford Hospital Medical Journal* : Vol. 34 : No. 3 , 202-206.

Available at: <https://scholarlycommons.henryford.com/hfhmedjournal/vol34/iss3/14>

This Article is brought to you for free and open access by Henry Ford Health System Scholarly Commons. It has been accepted for inclusion in Henry Ford Hospital Medical Journal by an authorized editor of Henry Ford Health System Scholarly Commons.

Azathioprine-Induced Reversible Severe Dyserythropoiesis as a Cause of Anemia

Sundara B.K. Raman, MD,* Joseph P. Abraham, MD,† Sheikh M. Saeed, MD,* and Maria Sawdyk, MD†

A 43-year-old woman with a 20-year history of systemic lupus erythematosus was treated with azathioprine for progressive complications of the disease. She developed pancytopenia within four weeks after starting azathioprine therapy. Bone marrow examination showed marked dyserythropoiesis and varying degrees of marrow hypoplasia. Changes seen in normoblasts consisted of nuclear buds, multinucleation, Howell-Jolly bodies, and abnormal mitoses. Azathioprine was discontinued. Peripheral blood counts improved in the next four weeks. A progress bone marrow examination six weeks later showed marked improvement in red blood cell abnormalities. An additional bone marrow examination performed four months after discontinuation of azathioprine showed complete disappearance of the dyspoietic changes in the red cell precursors despite continued clinical deterioration.

Three patients who were treated with azathioprine to prevent transplant rejection showed similar dyspoietic changes in erythroid precursors associated with anemia. (Henry Ford Hosp Med J 1986;34:202-6)

Peripheral blood macrocytosis associated with macronormoblastic and megaloblastoid changes in bone marrow has been well studied and reported in patients receiving azathioprine. A few cases of red cell hypoplasia have also been encountered. However, severe erythroid dyspoiesis in the absence of significant macrocytic anemia and megaloblastic changes due to azathioprine are unusual findings. Our report discusses a patient with long-standing systemic lupus erythematosus who developed such a complication with azathioprine therapy.

Case Report

A 43-year-old woman with a 20-year history of systemic lupus erythematosus was treated with corticosteroids and salicylates during the early stages of her disease. Corticosteroids were given intermittently at that time. During the seven years before her admission to Henry Ford Hospital in March 1982, she was treated regularly with 3 to 5 mg/day of prednisone and one tablet three times daily of hydroxychloroquine sulfate. Prednisone dosage was tapered in the early part of 1982 because of side-effects. On admission she showed evidence of vasospasm in the upper extremities.

The patient's medication was changed to 100 mg/day of azathioprine, and prednisone and hydroxychloroquine sulfate were continued in low doses. At this time the patient's hematology profile was as follows: hemoglobin 12.4 g/dL; mean corpuscular volume (MCV) 92; WBC

4,600/ μ L; differential white count of 54% polymorphonuclear neutrophil leukocytes (PMN), 6% bands, 29% lymphocytes, 6% monocytes, 3% eosinophils, and 2% basophils; and platelet count 175,000/ μ L. Coagulation and chemical parameters were within normal limits. Total protein was 5.1; albumin 2.7 and globulin 2.4; A:G ratio was 1:1.

During the next month the patient's hemoglobin gradually fell from 12.4 to 8.4 g/dL; WBC count declined from 4,600 to 1,400/ μ L; and platelet count declined to 93,000/ μ L. Her MCV gradually increased and remained above 104. Peripheral blood smear showed modest macrocytosis and only slight megalocytosis. Differential white count showed 35% PMN, 5% bands, 38% lymphocytes, 15% monocytes, 4% eosinophils, and 3% basophils.

A bone marrow aspirate and biopsy at this time revealed 40% cellularity with a myeloid to erythroid (M:E) ratio of 0.5:1. Granulocytes were slightly decreased with some left shift. Megakaryocytes were adequate. Erythroid precursors showed slight macronormoblastic changes with only occasional megaloblasts, but a large number of erythroblasts (37% of marrow hemopoietic elements) disclosed extensive nuclear pleomorphic changes (Figs 1 through 5). Ham's test was negative, and osmotic fragility was normal.

Submitted for publication: June 25, 1986.

Accepted for publication: July 24, 1986.

*Department of Hematopathology, Henry Ford Hospital.

†Department of Hematology, Henry Ford Hospital.

Address correspondence to Dr Raman, Department of Hematopathology, Henry Ford Hospital, 2799 W Grand Blvd, Detroit, MI 48202.

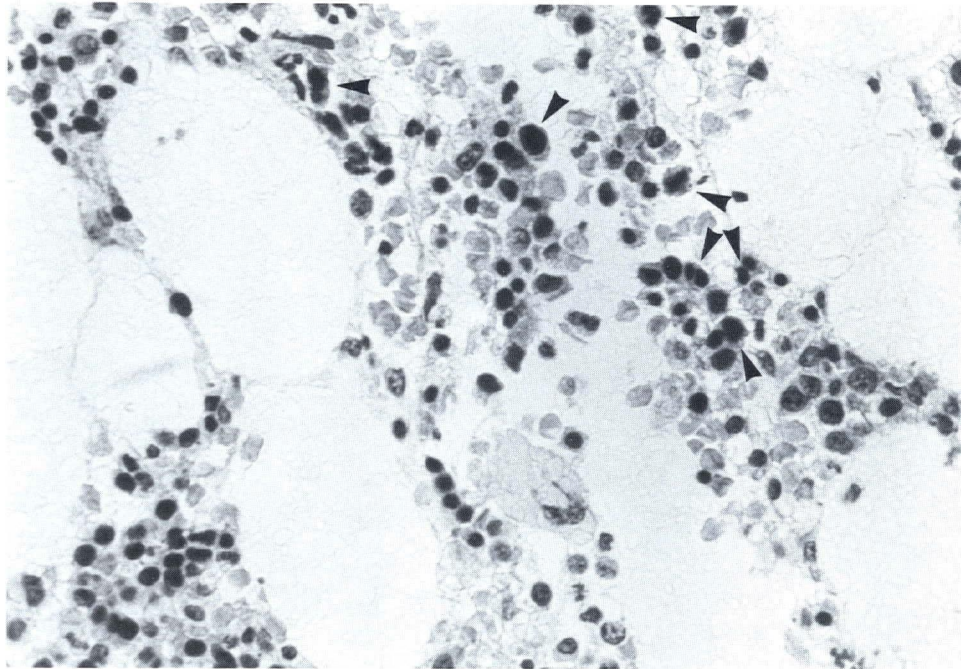


Fig 1—Section from bone marrow after onset of pancytopenia showing prominent erythroid islands with nuclear pleomorphism (arrows) (hematoxylin-eosin stain) (X400).

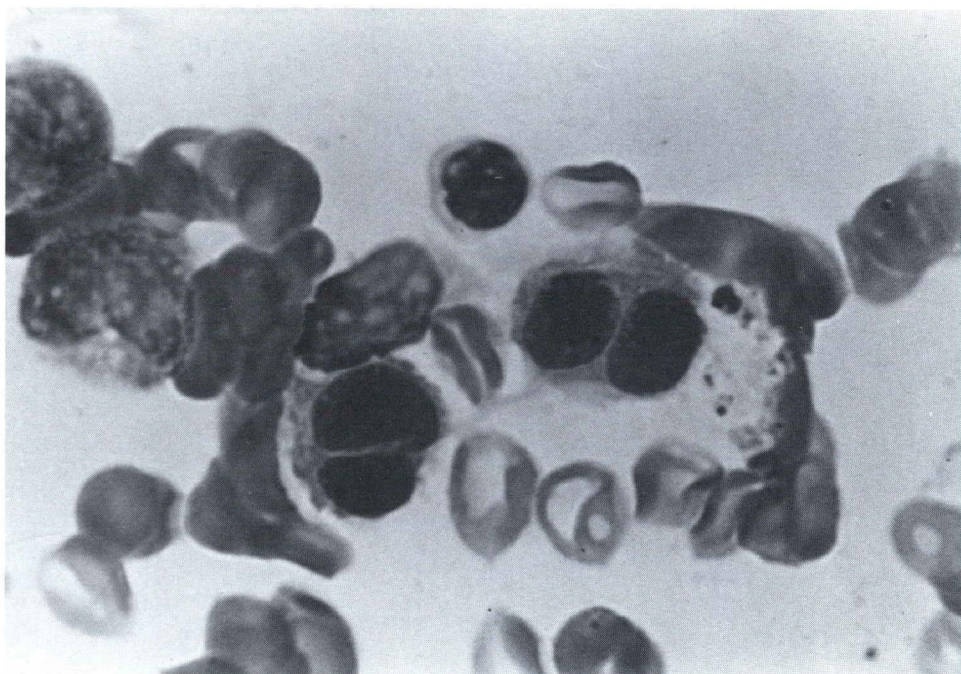


Fig 2—Binucleated erythroblasts were preponderant in the smears (Leishman's stain) (X1000).

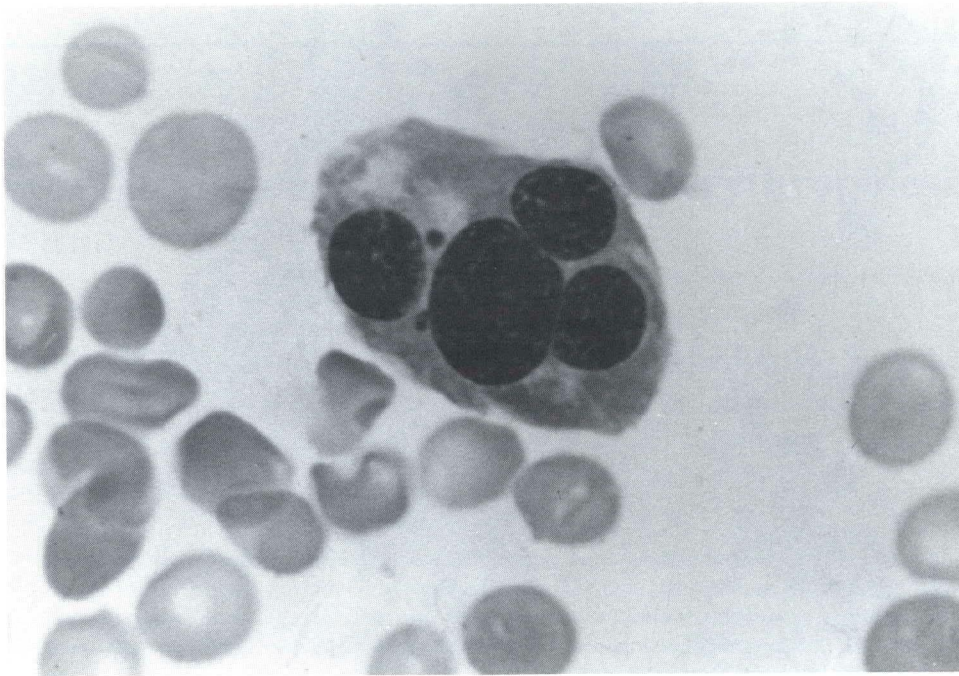


Fig 3—Giant multinucleated erythroblasts were frequently seen (Leishman's stain) (X1000).

Azathioprine was discontinued, and the patient was maintained on steroids. During the next six weeks her WBC, hemoglobin, and platelet count rose to 6,000/ μ L, 11.5 g/dL, and 154,000/ μ L, respectively. MCV was 100. A repeat bone marrow aspirate showed a marked decrease in erythroid pleomorphic changes. Granulocytes were well

represented, and platelet-forming megakaryocytes were seen more frequently. M:E ratio was 1.6:1.

During the next four months the patient's general condition deteriorated progressively from her primary disease, and she developed thromboemboli and infectious complications. Her hemoglobin and platelet

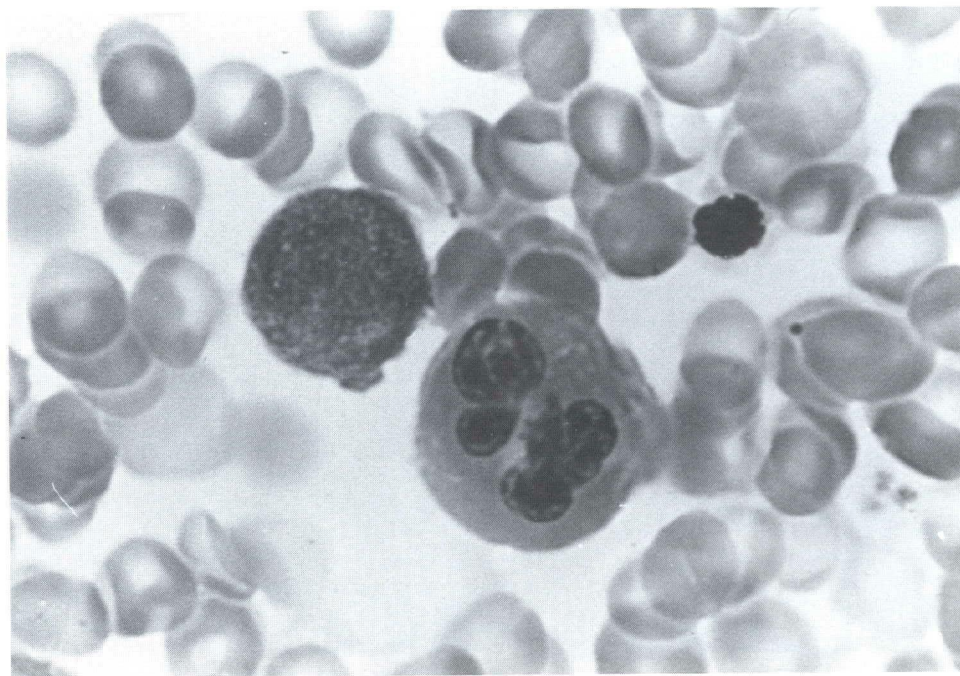


Fig 4—Large erythroblasts with numerous nuclear buds were also frequently seen (Leishman's stain) (X1000).

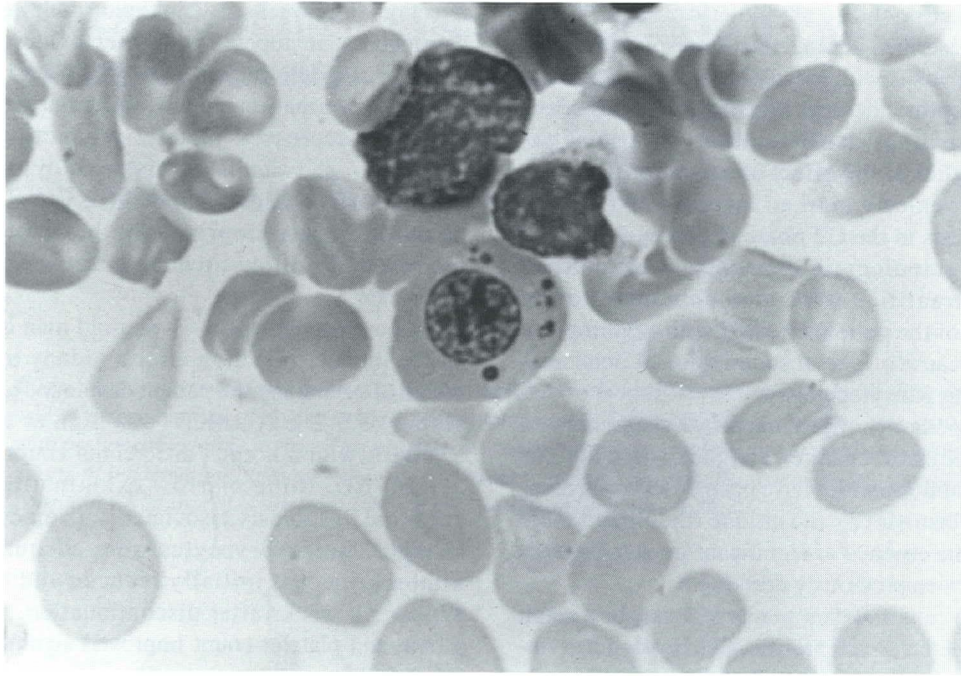


Fig 5—An erythroid precursor showing multiple Howell-Jolly bodies (Leishman's stain) (X1000).

count remained low at 10.2 g/dL and 123,000/ μ L. Total and differential WBC counts were normal. A third bone marrow aspirate performed four months after discontinuation of azathioprine showed complete disappearance of dyspoietic changes in erythroblasts (Fig 6). The patient died a month later of thromboembolic complications.

Discussion

Since its introduction and approved use for prevention of renal transplantation rejection, azathioprine has also been used in the treatment of a number of diseases including autoimmune disorders. Several toxic effects of the drug have been reported,

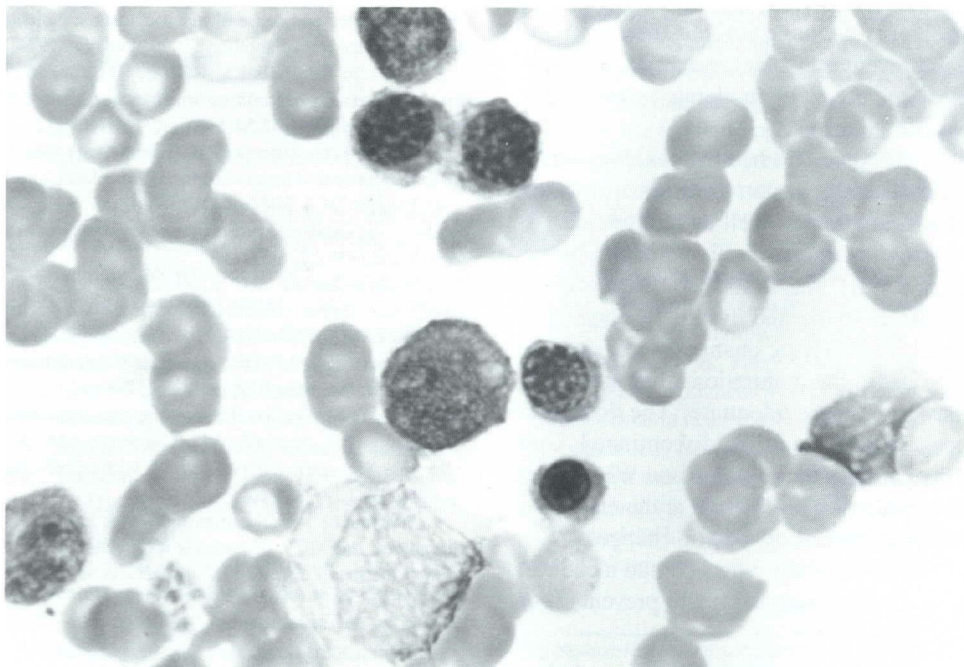


Fig 6—Bone marrow aspirate seven months after discontinuation of azathioprine showing essentially slightly macronormoblastic erythropoiesis with no evidence of dyspoiesis (Leishman's stain) (X1000).

particularly those affecting the hematopoietic system. Wickramasinghe et al (1) described several renal transplant patients who developed macrocytosis with megaloblastic changes in the marrow during azathioprine therapy. Macrocytosis with selective erythroid hypoplasia has also been observed in some patients (2-4). Later studies of the effect of azathioprine on the marrow cell cycle revealed a marked increase in the early polychromic normoblasts in the G2 phase of cell cycle (5) and minimal change in granulocytic elements. Well-defined chromosomal abnormalities were also demonstrated in erythroblasts in 80% of the patients treated with azathioprine (6). Azathioprine can cause a general suppression of bone marrow (7,8) with resulting pancytopenia.

Our patient developed only slight macrocytosis associated with minimal megaloblastic changes and pancytopenia. Although minor nuclear abnormalities have been observed in association with megaloblastosis (2), the unique finding of severe dyserythropoiesis in the absence of significant megaloblastosis in our patient has not been previously described.

Changes seen in red cells and their precursors may be a result of alterations in the kinetics of cell proliferation involving erythroid stem cells as well as more primitive hemopoietic stem cells (5,9). The changes previously reported appear to develop slowly as the drug is continued. In our patient the severe changes occurred within a relatively short period after azathioprine therapy was started, but disappeared within a few months after the drug was discontinued. Thus, our case differs significantly from the usually observed findings. This peculiar occurrence could be due to the presence of a clone of multipotent stem cells or erythropoietic stem cells with an unusual sensitivity to azathioprine (9). This may also account for occasionally, rapidly developing generalized marrow hypoplasia or selective red cell hypoplasia in patients on azathioprine therapy.

During the last three years we have studied three patients receiving azathioprine to prevent transplant rejection. These patients developed anemia associated with moderate to severe dyserythropoietic changes in the marrow.

One patient, a 30-year-old man who had had a kidney transplant for end-stage renal disease, was on azathioprine for six weeks when he developed anemia as well as leukopenia. At the time of the bone marrow examination his hemoglobin was 5.2 g/dL; MCV was 82; and WBC was 2,800/ μ L. Bone marrow examination showed moderate to marked dyspoietic changes in the erythroid precursors. Megaloblastic changes were not seen. Granulocytic cell line showed slight maturation arrest at the neutrophil stage. Megakaryocytes were adequate. The dosage of azathioprine was reduced initially and then discontinued. During the next six weeks the patient's hemoglobin and WBC count improved. A repeat bone marrow examination at the end of six weeks showed only minimal residual dyspoietic changes.

In another case, a 37-year-old man who had had a cadaver kidney transplant was on azathioprine therapy to prevent organ

rejection. Four weeks after initiation of the treatment, the patient developed pancytopenia with a hemoglobin of 4.9 g/dL; WBC of 1,700/ μ L; platelet count of 61,000/ μ L; and MCV of 89. Bone marrow examination showed mild maturation arrest in granulocytes, decreased platelet production found by megakaryocytes, and significant erythroid dyspoiesis with minimal megaloblastic changes. Approximately five weeks after discontinuation of azathioprine, the hematological parameters improved. A follow-up bone marrow examination was not performed.

Another patient was a 43-year-old man on azathioprine therapy to prevent rejection after a kidney transplant. Within a month after therapy the patient developed anemia with a hemoglobin of 6.2 g/dL; MCV was high at 116; and WBC was 5,100/ μ L with a normal differential count. Platelet count was 31,000/ μ L. Bone marrow examination showed marked erythroid dyspoiesis associated with moderate megaloblastic changes. Megakaryocytes were adequate. The dosage of azathioprine was initially reduced and later discontinued. Within six weeks after discontinuation, the patient's hemoglobin and platelet count improved significantly. MCV fell to 98. A follow-up bone marrow examination was not performed.

The limited observations reported here suggest that azathioprine can occasionally cause severe red cell dyspoiesis with resulting anemia in addition to causing macrocytosis and red cell hypoplasia. The apparent reversibility of this complication indicates that close monitoring of such patients is mandatory.

References

1. Wickramasinghe SN, Dodsworth H, Rault RMJ, Hulme B. Observations on the incidence and cause of macrocytosis in patients on azathioprine therapy following renal transplantation. *Transplantation* 1974;18:443-6.
2. McGrath BP, Ibels LS, Raik E, Hargrave M, Mahony JF, Stewart JH. Erythroid toxicity of azathioprine: Macrocytosis and selective marrow hypoplasia. *Q J Med* 1975;44:57-63.
3. DeClerck YA, Ettenger RB, Ortega JA, Pennisi AJ. Macrocytosis and pure RBC anemia caused by azathioprine. *Am J Dis Child* 1980;134:377-9.
4. Hogge DE, Wilson DR, Shumak KH, Cattran DC. Reversible azathioprine-induced erythrocyte aplasia in a renal transplant recipient. *Can Med Assoc J* 1982;126:512-3.
5. Wickramasinghe SN. Effect of azathioprine on the cell cycle of haemopoietic cells. *Scand J Haematol* 1976;16:38-40.
6. Jensen MK, Huttel MS. Assessment of the effect of azathioprine on human bone marrow cells in vivo, combining chromosome studies and the micronucleus test. *Dan Med Bull* 1976;23:152-4.
7. Rosman M, Bertino JR. Azathioprine. *Ann Intern Med* 1973;79:694-700.
8. Bacon BR, Treuhaft WH, Goodman AM. Azathioprine-induced pancytopenia: Occurrence in two patients with connective tissue diseases. *Arch Intern Med* 1981;141:223-6.
9. Williams D, Wickramasinghe SN, Hulme B. Effects of azathioprine therapy on the MCV of patients with renal grafts: Evidence for alterations in the kinetics of erythropoiesis over a prolonged period. *Scand J Haematol* 1978;20:258-64.